

# Lipoma Arborescens of the Knee: Report of a Case with Full Range of Motion

Ahmad Ensafdaran\*, Amir Reza Vosoughi\*\*, Arash Khozai\*, Simin Torabi\*\*,  
Mohammad Reza Ensafdaran\*

\*Research Center for Bone and Joint Diseases, Department of Orthopedics,  
Chamran Hospital, Shiraz University of Medical Sciences, Shiraz, Iran

\*\*Department of Pathology and Shiraz Nephrology Urology Research Center,  
Shiraz University of Medical Sciences, Shiraz, Iran

## Abstract

This report describes a rare intra-articular benign tumor, lipoma arborescens, of the knee joint in a 21 year-old female. The patient suffered from left knee joint swelling for five years with occasional pain. Swelling was soft and boggy in the suprapatellar area. Motion of joint was complete. No abnormality was detected in any laboratory tests. MRI showed a large soft tissue density in the suprapatellar area with high signal intensity on T<sub>1</sub> and T<sub>2</sub> weighted images. Operative arthroscopy revealed a creamy brown hypertrophied synovium with diffuse papillary processes characterized by villous proliferation of the synovium infiltrated by mature fat tissue, chronic inflammatory cells and vessels as seen in the pathologic slides. Lipoma arborescens or villous lipomatous proliferation of the synovial membrane should be distinguished from other similar lipomatoid conditions such as synovial lipoma and Hoffa disease. Lipoma arborescens should be considered in patients with painless, slowly progressive swelling of a joint, especially the knee.

**Keywords:** Lipoma arborescens, Knee, Synovium

## Introduction

Lipoma arborescens is a very rare benign neoplasm of the synovium characterized by villous, polyploid, and lipomatous proliferation of the synovium with the subsynovial layer replaced by fat cells.<sup>1</sup> The term 'arborescens' originates from the Latin word *arbor* meaning tree, thus describing the tumor's characteristic tree-like morphology. This tumor

usually occurs in the knee but there are reports of involvement of other joints such as the hip, ankle, shoulder, elbow and wrist.<sup>2,3</sup> This benign tumor is mostly mono-articular, but there are several reports of bilateral knee involvement.<sup>4</sup> A case report with polyarticular involvement has also been reported.<sup>5</sup> The primary cause of lipoma arborescens remains unknown; however associated

### Corresponding Author:

Amir Reza Vosoughi, MD  
Research Center for Bone and  
Joint Diseases, Department of  
Orthopedic, Chamran Hospital,  
Shiraz University of Medical  
Sciences, Shiraz, Iran  
Tel / Fax: +98-711-6234504  
Tel: +98-917-313 2795  
E-mail:  
vosoughiar@hotmail.com

conditions have been reported which include local trauma, meniscal injuries, psoriatic arthritis, osteoarthritis, rheumatoid arthritis, diabetes mellitus and gout.<sup>1,6</sup>

It should be mentioned that we have not found any lipoma arborescens case reports in our region. Therefore, this case may be the first.

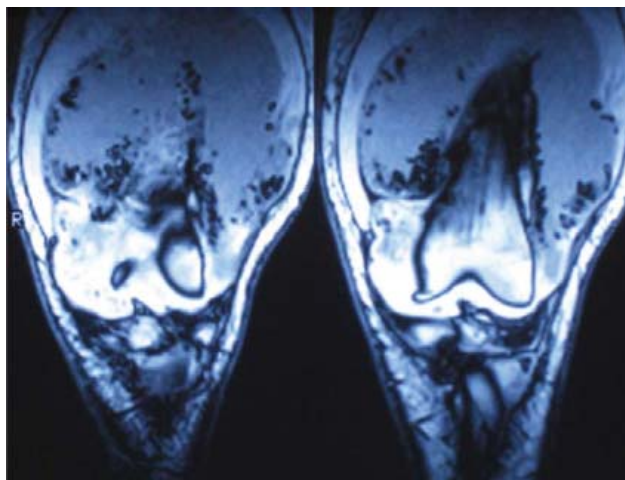
### Case report

A 21 year-old female presented with a five year history of left knee swelling and occasional pain. She had several episodes of exacerbation followed by remission and no history of catching or locking knee, limping or giving way. There were no constitutional or systematic symptoms.

On physical examination, soft boggy swelling with effusion in the suprapatellar area was noted. There was no tenderness or redness. Joint movements were not restricted or painful.

Laboratory test results which included white blood cell count (WBC), erythrocyte sedimentation rate (ESR), C-reactive protein (CRP), rheumatoid factor and uric acid were normal. No abnormalities in the joint aspiration tests including gram stain, culture and crystal were detected.

Plain radiographs of the left knee joint showed no remarkable changes except for a shadow of soft tissue swelling in the upper part of the knee. Magnetic resonance imaging (MRI) showed a large soft tissue density extending from the



**Figure 1.** Coronal view of T1-weighted MRI image shows soft tissue mass extending from the suprapatellar bursa to the fat pad.

suprapatellar bursa to the fat pad. The tumor exhibited a high signal intensity on T<sub>1</sub>-weighted images (Figure 1) and brightness on T<sub>2</sub>-weighted images (Figure 2). Based upon MRI appearance, the lesion was believed to be a synovial sarcoma.

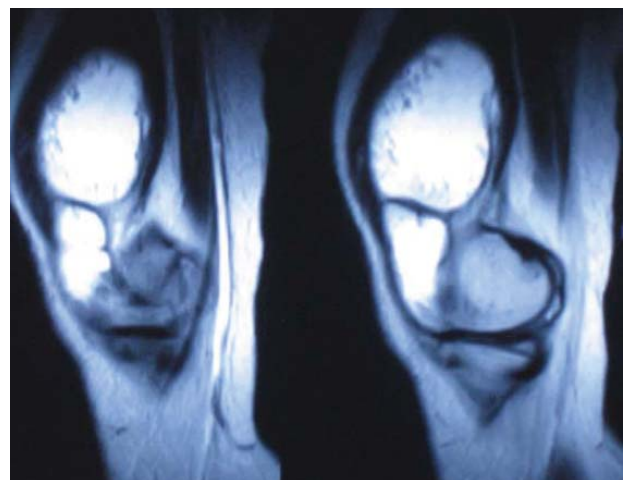The patient subsequently underwent an operative arthroscopy which revealed a creamy brown hypertrophied synovium with diffuse papillary processes, particularly in the suprapatellar pouch. Subsequently, synovectomy was performed using a combination of radiofrequency ablation and shaving.

Microscopic examination revealed diffuse villous hypertrophy and hyperplasia of the synovium. Extensive mature adipose tissue admixed with focal and patchy chronic inflammatory cells and vascular proliferations were seen under the synovial lining (Figures 3A and 3B).

The patient was asymptomatic at the six weeks post-op follow up.

### Discussion

Lipoma arborescens or villous lipomatous proliferation of the synovial membrane has been reported in patients between the ages of 9 to 68 years and is equally common in women and men.<sup>6</sup> Patients with lipoma arborescens usually present with a painless, long-standing, slowly progressive swelling of a joint; especially the knee with intermittent effusion. Range of motion may be



**Figure 2.** Sagittal view of T2-weighted MRI image shows a high signal intensity soft tissue mass extending from the suprapatellar pouch to the fat pad.

restricted; however the presented case had full range of motion.

Laboratory tests including WBC, ESR, CRP, uric acid and rheumatoid factor are normal. Plain x-rays may show a soft tissue density but are more practical for excluding other causes of joint swelling. MRI, the best non-invasive diagnostic method, shows a villous synovial mass or mass-like subsynovial deposit with signal intensity similar to that of fat.<sup>7</sup>

Lipoma arborescens should be differentiated from other similar diseases such as synovial lipoma and Hoffa disease. Hoffa disease is a syndrome of infrapatellar fat pad impingement as described by Hoffa in 1904. A minor trauma to the fat pad results in an acute inflammatory response with swelling. The involved fat pad is susceptible to impingement between articular surfaces of the patella and femur or between the tibia and femur. Repeated trauma results in fat pad enlargement with hemorrhage, fat necrosis, and ultimately fibrosis with a tumor-like appearance.<sup>8</sup> MRI displays low signal intensity areas on both T<sub>1</sub>-weighted and T<sub>2</sub>-weighted images. The primary treatment is arthroscopic or open resection of the lesion.

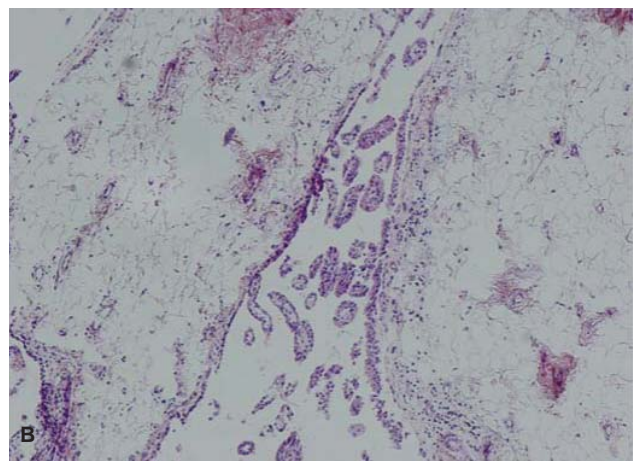
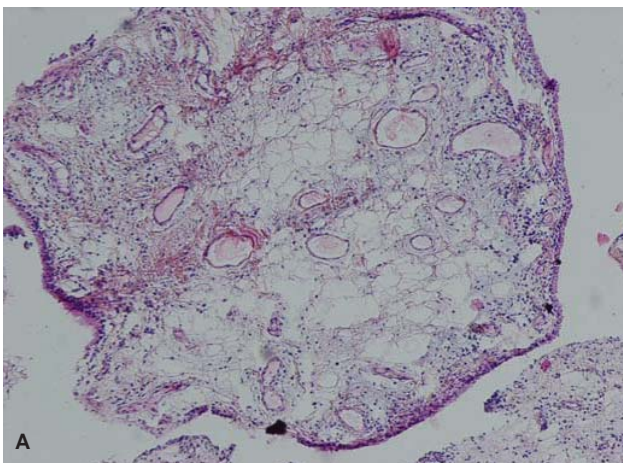
Intra-articular synovial lipoma mainly develops in the knee joint, typically arises from the fat pad area of the suprapatellar pouch<sup>9</sup> by penetrating the synovial membrane or as a result of fat overgrowth within the intra-articular synovial tissue.<sup>10</sup> MRI images of intra-articular synovial lipoma and fat

tissue appear as high signal intensities in both T<sub>1</sub> and T<sub>2</sub>-weighted images. Although high signal intensity is seen in both synovial lipoma and lipoma arborescens, villous lipomatous proliferation of the synovial membrane has a characteristic morphological appearance as described above. Histopathologically, it is difficult to differentiate lipoma arborescens from intra-articular synovial lipoma because of their similar appearance: a collection of mature fat cells covered by fibrous tissues of the synovial membrane. The most important point for distinction between these two lesions is macroscopic appearance. Intra-articular synovial lipoma usually appears as a small, yellowish, solitary polyp-like mass, round to oval in shape, with a short stalk; while lipoma arborescens usually appears as a large, frond-like mass. Similar to Hoffa disease, the treatment of choice for intra-articular lipoma is resection either by arthroscopy or open surgery.

Surgical treatment of lipoma arborescens is either an arthroscopic synovectomy or open surgery synovectomy with short-term morbidity. Moreover, medical management with intra-articular injection of radio-active compounds such as Yttrium 90 or steroids may lead to short term resolution of symptoms.<sup>10</sup>

### Acknowledgement

The authors are grateful to Dr. N. Azarpira for her help in preparing the histopathology figures.



**Figure 3A and 3B.** Villous proliferation of the synovium with diffuse replacement of the subsynovial tissue by mature fat cells with scattered inflammatory cells and small blood vessel proliferation (A: H&E, 400×); (B: H&E, 100×).

## References

1. Davies AP, Blewitt N. Lipoma arborescens of the knee. *Knee* 2005;12(5): 394-6.
2. Murphey MD, Carroll JF, Flemming DJ, Pope TL, Gannon FH, Kransdorf MJ. From the archives of the AFIP: Benign musculoskeletal lipomatous lesions. *Radiographics* 2004;24(5):1433-66.
3. Chae EY, Chung HW, Shin MJ, Lee SH. Lipoma arborescens of the glenohumeral joint causing bone erosion: MRI features with gadolinium enhancement. *Skeletal Radiol* 2009;38(8):815-8.
4. Yan CH, Wong JW, Yip DK. Bilateral knee lipoma arborescens: a case report. *J Orthop Surg (Hong Kong)* 2008;16(1):107-10.
5. Santiago M, Passos AS, Medeiros AF, Sá D, Correia Silva TM, Fernandes JL. Polyarticular lipoma arborescens with inflammatory synovitis. *J Clin Rheumatol* 2009;15(6):306-8.
6. Kloen P, Keel SB, Chandler HP, Geiger RH, Zarins B, Rosenberg AE. Lipoma arborescens of the knee. *J Bone Joint Surg Br* 1998;80(2):298-301.
7. Alkubaidan FO, Heffernan EJ, Munk PL. Radiology for the surgeon: Musculoskeletal case 41. Lipoma arborescens. *Can J Surg* 2008;51(3): 207-8.
8. Metheny JA, Mayor MB. Hoffa disease: Chronic impingement of the infrapatellar fat pad. *Am J Knee Surg* 1998;1:134-39.
9. Matsumoto K, Okabe H, Ishizawa M, Hiraoka S. Intra-articular lipoma of the knee joint. A case report. *J Bone Joint Surg Am* 2001;83-A (1):101-5.
10. Hirano K, Deguchi M, Kanamono T. Intra-articular synovial lipoma of the knee joint (located in the lateral recess): A case report and review of the literature. *Knee* 2007;14(1):63-7.